

## PIGMENTED 'BLACK' ADENOMA: A RARE CAUSE OF CONN'S SYNDROME

Saladina JJ<sup>1</sup>, Rohaizak M<sup>1</sup>, Jasmi AY<sup>1</sup>, Sellymiah A<sup>2</sup>, Aishah MAS<sup>2</sup>, Das S<sup>3</sup>, Naqiyah I<sup>1</sup>, Shahrin NS<sup>1</sup>

1 Surgery, Endocrine and Breast Surgery Unit, Universiti Kebangsaan Malaysia Medical Center, Kuala Lumpur, Malaysia.

2 Pathology, Universiti Kebangsaan Malaysia Medical Center, Kuala Lumpur, Malaysia.

3 Anatomy, Universiti Kebangsaan Malaysia Medical Center. Kuala Lumpur, Malaysia.

### ABSTRACT

Presence of a hypofunctioning pigmented adenoma are commonly asymptomatic and is usually only found during an autopsy. In contrast, hyperfunctioning pigmented adenoma is a rare clinical entity and in the majority of cases results in Cushing's syndrome. In this case study, we report a 66-year-old male who presented instead with the clinical and biochemical features of Conn's syndrome. On laparoscopic adrenalectomy, it was found that the tumour had a functioning black adenoma which does not usually present with Conn's syndrome but rather to that of a Cushing's. The intraoperative changes and histopathological findings are discussed.

**KEYWORDS:** *Conn's adenoma, pigmented, lesion, laparoscopy, histopathology, surgery*

### Correspondence:

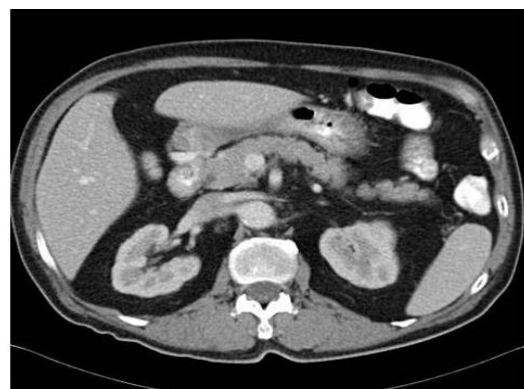Dr. Saladina Jaszle Jasmin  
Endocrine and Breast Unit  
Department of Surgery  
UKM Medical Centre.  
Jalan Yaakob Latiff, Bandar Tun Razak  
Cheras, 56000, Kuala Lumpur  
Tel:+603-91455555 / Fax:+603-91456684  
Email: saladina\_hukm@yahoo.com

### Introduction

Pigmented lesions of the adrenal gland which includes myelolipoma, metastatic melanoma, haemangioma and haematoma [1] are easily distinguished from the more rarer conditions (through the use of histological analyses), such as the pigmented nodule and the black adenoma.

Adrenal adenoma is a benign lesion, being reported to be 3% within the general population [1]. While some adenomas are not functioning tumour (also called incidentalomas), adrenal adenomas may present with certain syndromes, which may include Cushing's, Conn's and hyperandrogenism. In Conn's syndrome the typical appearance of bright yellow tumour within the adrenal tissue is a common presentation. The

description of a pigmented 'black' adrenal adenoma is a rare variant of this condition. It is often associated with hypercortisolism and is very rarely due to hyperaldosteronism. Due to its rare incidence, only

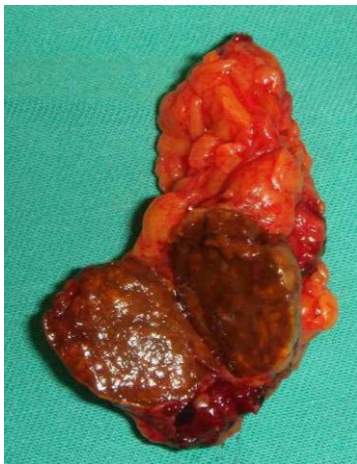

**Figure 1.** *Abdominal CT image of the tumour in the left adrenal gland*

twenty cases of 'black' adrenal adenoma have ever been reported. Of these reported cases, only two were aldosterone producing tumour [2]. In this paper, we highlight an interesting case of adrenal tumour which was found to be of the rare 'black' adrenal adenoma types.

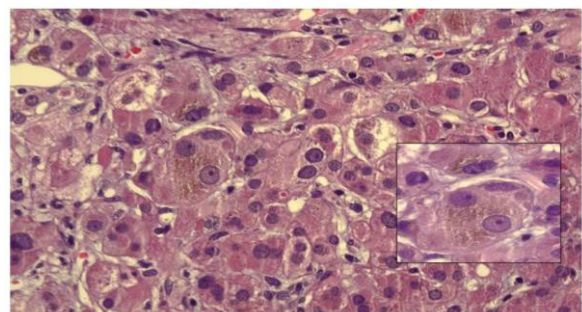
### Case report

A 66-year-old man with a history of hypertension for the past 8 years, presented with resistant hypertension despite being treated using a variety and combination of antihypertensive medications. He was also noted to have recurrent episode of hypokalaemia. Biochemical investigation showed a normal cortisol level with a raised serum aldosterone and a low level of serum renin. Following fluorodrocortisone stimulation test, the aldosterone renin ratio was measured at  $> 32 \mu\text{m}$  thus confirming the diagnosis of conns adenoma. Computed tomography scan of the abdomen showed a well defined enhancing nodular lesion in the left adrenal gland measuring 2 cm x 1.8 cm x 2 cm (Figure 1). We



**Figure 2.** Macroscopic picture of the specimen removed from the left adrenal gland showing Conn's adenoma proceeded with laparoscopic adrenalectomy. Intraoperatively, we observed a black, well defined lesion in the left adrenal gland. During the surgical manipulation, the intraoperative blood pressure was labile and the patient required fluid support and inotropic

support to stabilize his condition. After his blood pressure was stabilized, he was taken off the inotropic support 2 hours post operatively. As expected, the potassium level normalized soon after the surgery and remained at normal levels thereafter. Post operative recovery was good and his antihypertensive medication requirement was reduced to a single agent. Histopathological examination revealed a brown nodular tumour measuring 3 cm x 2 cm x 2 cm, weighing 7.9 gm (Figure 2). The whole adrenal gland measured 6 cm x 1.5 cm x 0.5 cm. Macroscopic appearance revealed a well circumscribed encapsulated tumour arising from the cortex of the adrenal gland. Microscopically, the tumour was composed of sheets and compact nests of neoplastic cells with small round and oval nuclei with prominent nucleoli (Figure 3). Most of the cells had abundant granular eosinophilic cytoplasm with some vesicular cytoplasm. Brown pigment was observed in most of the cells within the cytoplasm. There was absence of necrosis, haemorrhage or mitotic figures. Capsular or vascular invasion were absent. The morphological appearance with adjacent atrophic non tumour adrenal cortex supported the diagnosis of adrenal cortical adenoma.



**Figure 3.** The neoplastic cells exhibiting round to oval nuclei with small prominent nucleoli and abundant granular eosinophilic cytoplasm. Some of the cells contain melanin as evidenced by the presence of brown pigments within the cytoplasm (arrow). (H&E stain; x100, insert x400)

### Discussion

Adrenal adenoma is a benign lesion of the adrenal gland that arises from the adrenal cortex. In black

adrenal adenoma, hypersecretion of cortisol has been reported to be 9 times more common than aldosterone [2,3]. In these groups of adenoma, 80% of the cytoplasm contains microscopic fat. In addition, there appears to be an abundance of myxoid and myelolipoma [4]. These features are not present in aldosterone producing black adenoma. The reason for this remains uncertain even though in both lesions, the increase in eosinophilic cytoplasm and lipofuscin pigment within these cells are clearly observed.

It is unknown as to why in this case; a black adenoma had resulted in an increase in aldosterone levels, instead of the usual cortisol levels, which was evident by the uncontrolled hypertensive condition observed. Although the prognosis and behaviour of “black adenoma” is unknown due to the rarity of this condition, similarities in the cellular morphology between Conn’s adenoma and aldosterone producing black adrenal adenoma suggest that this tumour would behave as that of a benign lesion [1, 3, 5, 6]. The biochemical and physiological changes in black adenoma are said to be similar to the common adrenal adenoma which possesses a canary yellow appearance.

In our patient, the histopathological findings differed from earlier research reports [2,3,5,6]. The dark appearing adrenal adenoma was said to be due to the presence of intracytoplasmic lipofuscin in the hypertrophied cortical cells of the zona reticularis [2,3]. In our case however, the hyperpigmentation was not due to intracytoplasmic lipofuscin, instead, it was due to the presence of melanin in the cytoplasm that gave out the brown pigment. This feature was best appreciated when viewed using Haematoxylin and Eosin (H & E) staining as shown in Figure 3 .

## Conclusions

Adrenal tumor as a differential diagnosis should be considered in patients with hypertensive conditions who do not respond to medication. Although typically, an increase in cortisol levels is usually expected in “black adenomas”, an increase in aldosterone alone cannot exclude this condition completely.

## References

- 1 Cao Dengfeng, Dehner LP. The Adrenal gland. The Washington Manual of Surgical Pathology 2008; 345: 348-9.
- 2 Sienkowski IK, Watkins RM, Anderson VE. Primary tumorous aldosteronism due to a black adrenal adenoma: a light and electron microscopic study. *J Clin Pathol* 1984;37:143-9.
- 3 Prince EA, Yoo DC, DeLellis RA, Mayo-Smith WW. CT and PET appearance of a pigmented “ black” adrenal adenoma in a patient with lung cancer. *Clin Radiol* 2007;62:1229-31.
- 4 Armand R, Cappola AR, Horenstein RB, Drachenberg CB, Sasano H, Papadimitriou JC et al. Adrenal Cortical adenoma with excess black pigment deposition, combine with myelolipoma and clinical Cushing’s syndrome. *Int J Surg Pathol* 2004;12:57-61.
- 5 Komiya I, Takasu N, Aizawa T, Yamada T, Koizumi Y, Hashizume K, et al. Black (or brown) adrenal cortical adenoma. It’s characteristic features on computed tomography and endocrine data. *J Clin Endocrinol Metab* 1985, 61:711-7.
- 6 Lam KY, Wat MS. Adrenal cortical black adenoma: report of two cases and review of the literature. *J Urol Pathol* 1996,4:183-90.